

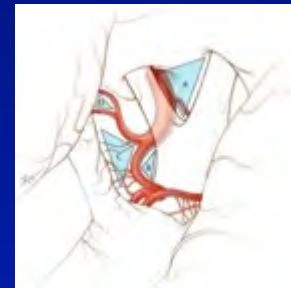
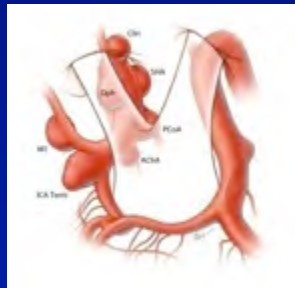

# Contralateral Pterional Microsurgical Approach for Bilateral Supratentorial Aneurysms:

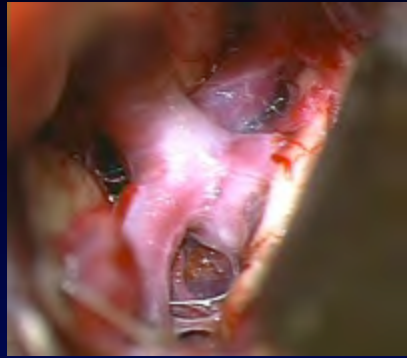
Outcomes Comparison between 60 Consecutive Patients with 144 Aneurysms  
and 2144 Standard Aneurysm Cases



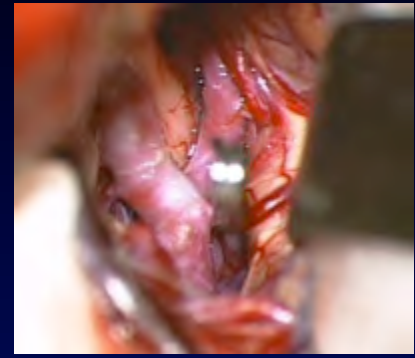**Rafael J. Tamargo, M.D., F.A.C.S.**  
**Walter E. Dandy Professor of Neurosurgery**  
**Professor of Neurosurgery and Otolaryngology**

The Johns Hopkins University School of Medicine  
Division of Cerebrovascular Neurosurgery  
Department of Neurosurgery  
Baltimore, Maryland





# Incidence of Multiple/Bilateral Supratentorial Aneurysms

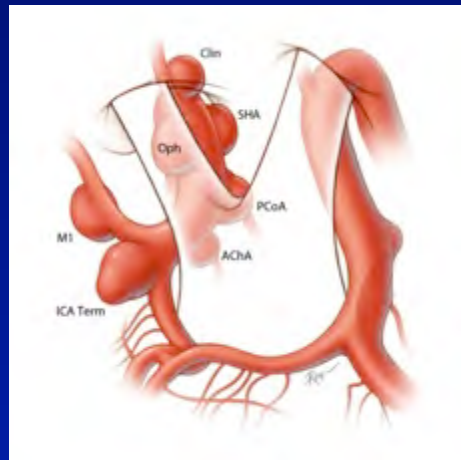


## Multiple aneurysms:


Estimated average prevalence of 25% (range 5-34%)

## Bilateral supratentorial aneurysms:

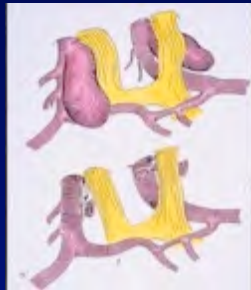
Estimated average prevalence of 7% (range 1-14%)



# First Reports of Contralateral Approaches for Bilateral Aneurysms: 1977 and 1981



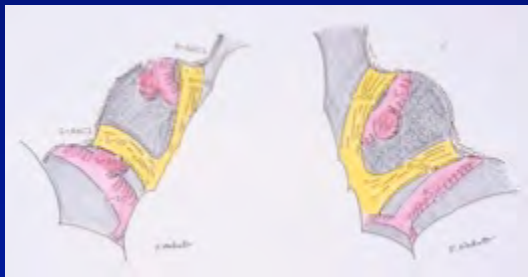- 1977: MG Yasargil et al. (Zurich, Switzerland)



*One case of bilateral OphA aneurysms*

Yasargil MG et al. Surg Neurol 8:155, 1977

- 1981: S Nakao et al. (Osaka, Japan)



*Two cases of contralateral OphA aneurysms*

Nakao S et al. J Neurosurg 54:532, 1981

# Contralateral Approaches for Aneurysms: 16 Case Reports and 12 Series (1977-2010)

- 16 case reports (1-4 cases per report)
- 12 series (9-51 cases per series):
  - 1) MG Yasargil (**Switzerland**) Microneurosurgery, 1984 (11)
  - 2) J Vajda et al. (**Hungary**) Neurosurgery 22:662, 1988 (39)
  - 3) JC Lynch, R Andrade (**Brazil**) Surg Neurol 39:120, 1993 (19)
  - 4) E de Oliveira et al. (**Brazil**) Acta Neurochir 138:1, 1996 (51)
  - 5) E Oshiro et al. (**Johns Hopkins, USA**) J Neurosurg 87:163, 1997 (9)
  - 6) G Fries et al. (**Germany**) Neurosurgery 41:333, 1997 (9)
  - 7) Y Kakizawa et al. (**Japan**) Neurosurgery 47:1130, 2000 (11)
  - 8) JHA McMahon et al. (**Australia**) J Clin Neurosci 8:319, 2001 (27)
  - 9) AA de Sousa et al. (**Brazil**) Surg Neurol 63(S1):1, 2005 (30)
  - 10) R Santana, L Casulari (**Italy**) J Neurosurg Sci 50: 1, 2006 (43)
  - 11) T Hong, Y Wang (**China**) Surg Neurol 72: S1-23, 2009 (8)
  - 12) A Rajesh et al. (**India**) Jl Clin Neuroscience 17: 1294, 2010 (10)

# Contralateral Approaches for Aneurysms: 16 Case Reports and 12 Series (1975-2010)

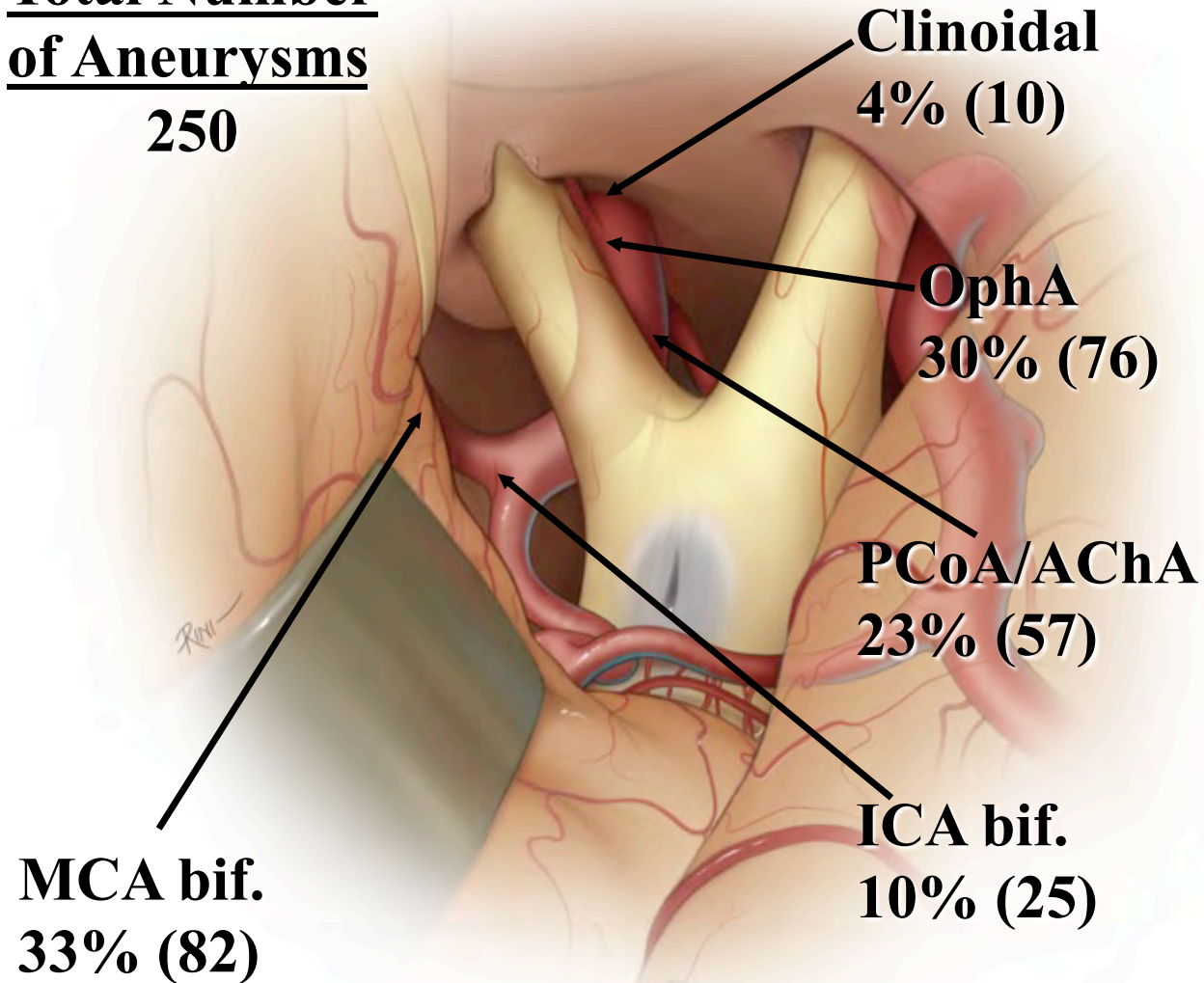
- 16 case reports (1-4 cases per report)
- 12 series (9-51 cases per series):
  - 1) MG Yasargil (**Switzerland**) Microneurosurgery, 1984 (11)
  - 2) J Vajda et al. (**Hungary**) Neurosurgery 22:662, 1988 (39)
  - 3) JC Lynch, R Andrade (**Brazil**) Surg Neurol 39:120, 1993 (19)
  - 4) E de Oliveira et al. (**Brazil**) Acta Neurochir 138:1, 1996 (51)
  - 5) E Oshiro et al. (**Johns Hopkins, USA**) J Neurosurg 87:163, 1997 (9)
  - 6) G Fries et al. (**Germany**) Neurosurgery 41:333, 1997 (9)
  - 7) Y Kakizawa et al. (**Japan**) Neurosurgery 47:1130, 2000 (11)
  - 8) JHA McMahon et al. (**Australia**) J Clin Neurosci 8:319, 2001 (27)
  - 9) AA de Sousa et al. (**Brazil**) Surg Neurol 63(S1):1, 2005 (30)
  - 10) R Santana, L Casulari (**Italy**) J Neurosurg Sci 50: 1, 2006 (43)
  - 11) T Hong, Y Wang (**China**) Surg Neurol 72: S1-23, 2009 (8)
  - 12) A Rajesh et al. (**India**) Jl Clin Neuroscience 17: 1294, 2010 (10)

# Review of the Literature (1977-2010)

## Distribution of Contralateral Aneurysms

**Total Number  
of Aneurysms**

**250**



# Cadaveric Anatomical Study and Early Series (9/23 patients)

Oshiro EM, Rini DA, Tamargo RJ  
*Jl Neurosurg* 87: 163, August 1997

- 16 adult cadaver heads:
  - 10 formalin-fixed specimens
  - 6 silicone-injected fresh specimens
- Pterional (frontosphenotemporal) craniotomies
- Anatomical morphometry and microsurgical dissection of contralateral corridors

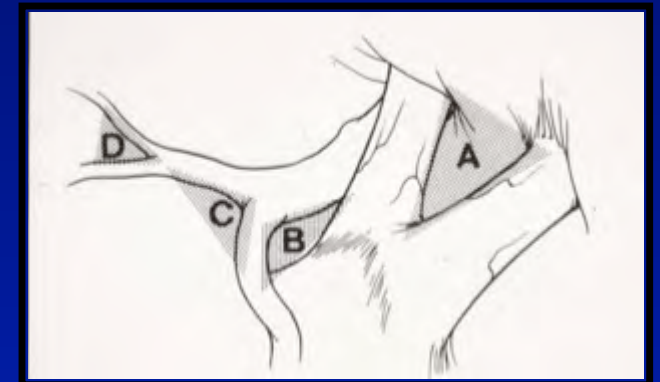
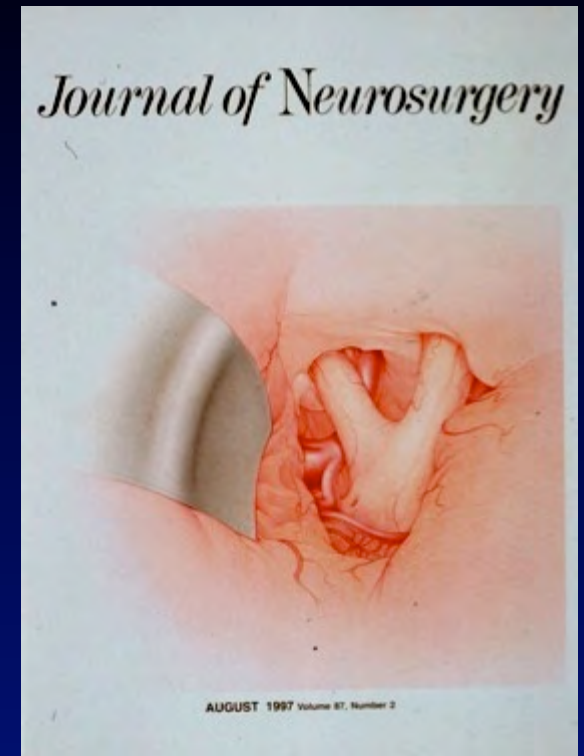


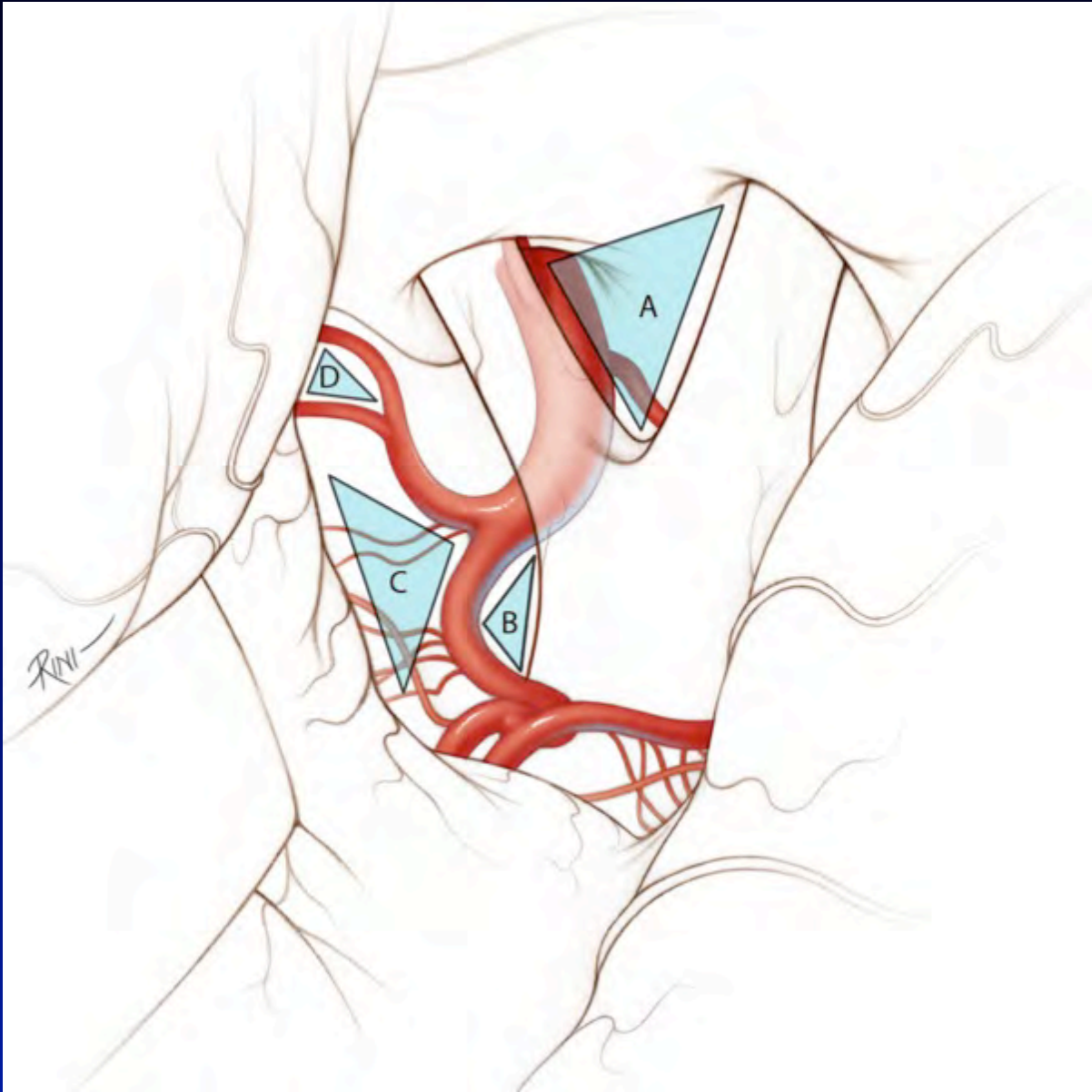
TABLE 1

*Summary of morphometric measurements obtained from a microsurgical anatomical study of contralateral exposure in 16 cadaver heads\**

Contralateral Anatomy	No. of Specimens	Range (mm)	Mean (mm)	Median (mm)
optic nerve length	16	6.0–14.5	9.9	10.0
falciform ligament width (largest dimension)	12	1.0–6.0	2.9	3.0
ICA diameter (at ICA bifurcation)	15	3.2–5.2	4.4	4.6
M <sub>1</sub> diameter (at ICA bifurcation)	16	3.2–4.8	3.8	3.8
A <sub>1</sub> diameter (at ICA bifurcation)	16	2.0–3.2	2.8	3.0
PCoA diameter	11	0.8–3.8	1.7	1.8
AChA diameter	10	0.5–1.2	0.9	1.0
supraclinoid ICA length	15	8.0–19.0	13.8	14.0
M <sub>1</sub> length	16	7.0–26.0	13.5	13.0
A <sub>1</sub> length	14	7.0–18.0	11.8	12.0
length of OA exposed	8	1.0–7.0	3.3	3.0

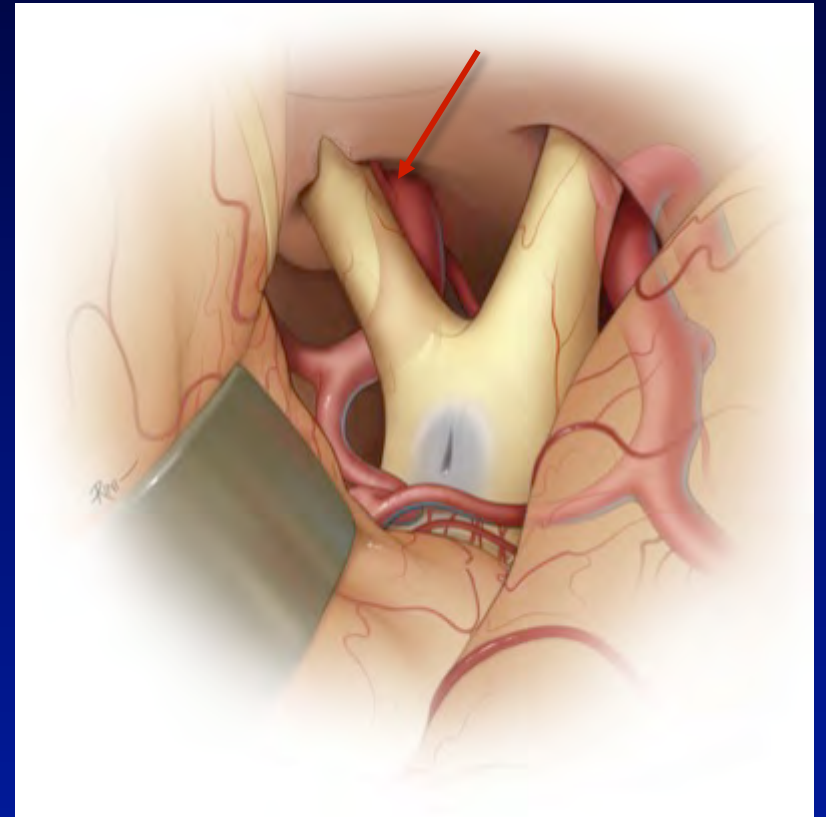
\* A<sub>1</sub> = proximal segment of the anterior cerebral artery; M<sub>1</sub> = proximal segment of the MCA.





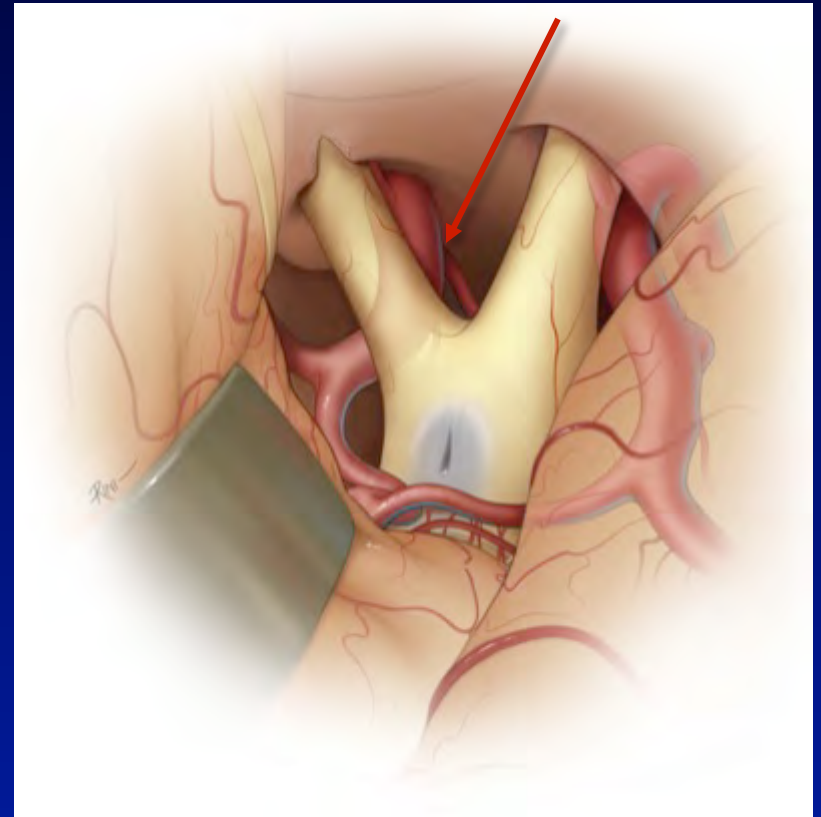
# Exposure of the Region of the Contralateral Ophthalmic Artery

- OphA origin exposed in 62% of specimens
- Optimum corridor is interoptic space
- Incision of falciform fold is critical
- Mobilization of optic nerve is necessary



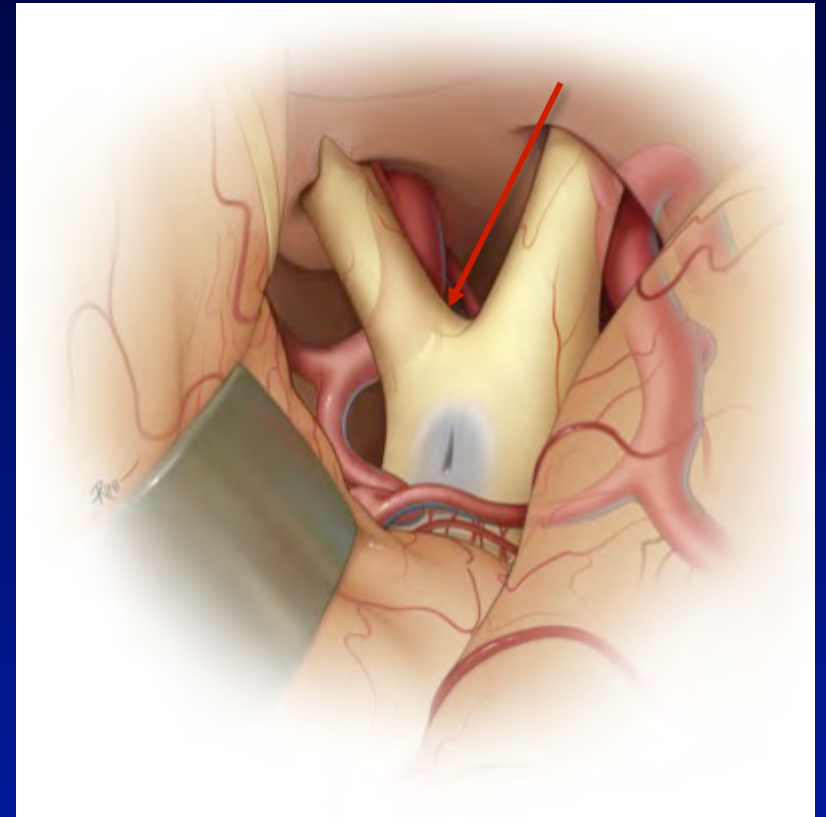
# Exposure of the Region of the Contralateral Posterior Communicating Artery

- PCoA origin exposed in 50% of specimens
- Optimum corridor is usually interoptic space and less commonly the opticocarotid space
- Incision of falciform fold is critical
- Mobilization of optic nerve is necessary



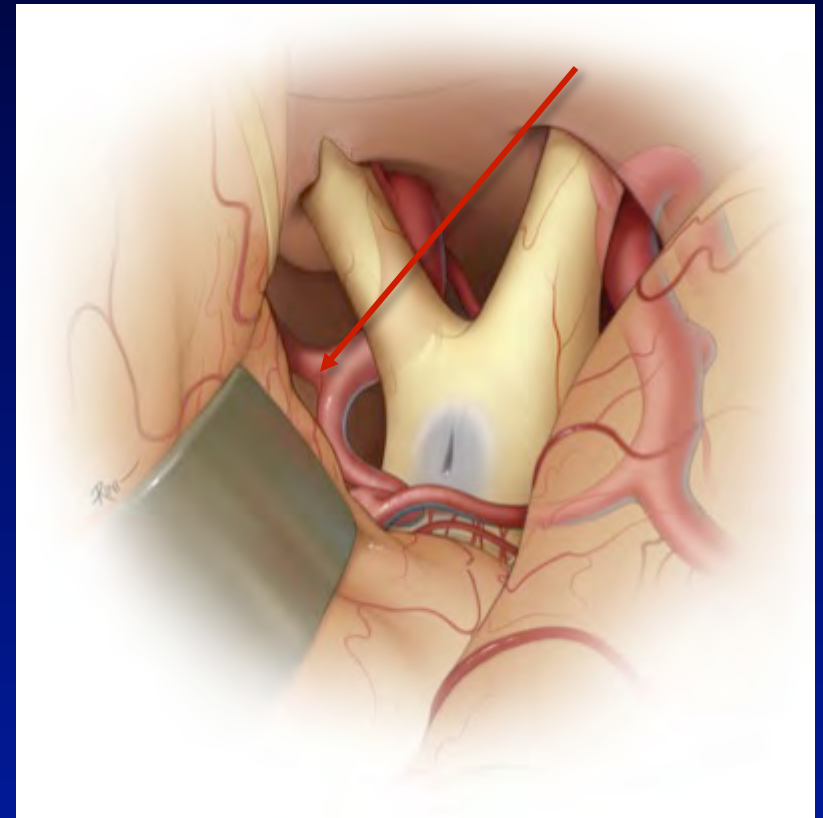
# Exposure of the Region of the Contralateral Anterior Choroidal Artery

- AChA origin exposed in 62% of specimens
- Optimum corridor is opticocarotid space
- Incision of falciform fold is critical
- Mobilization of optic nerve is necessary

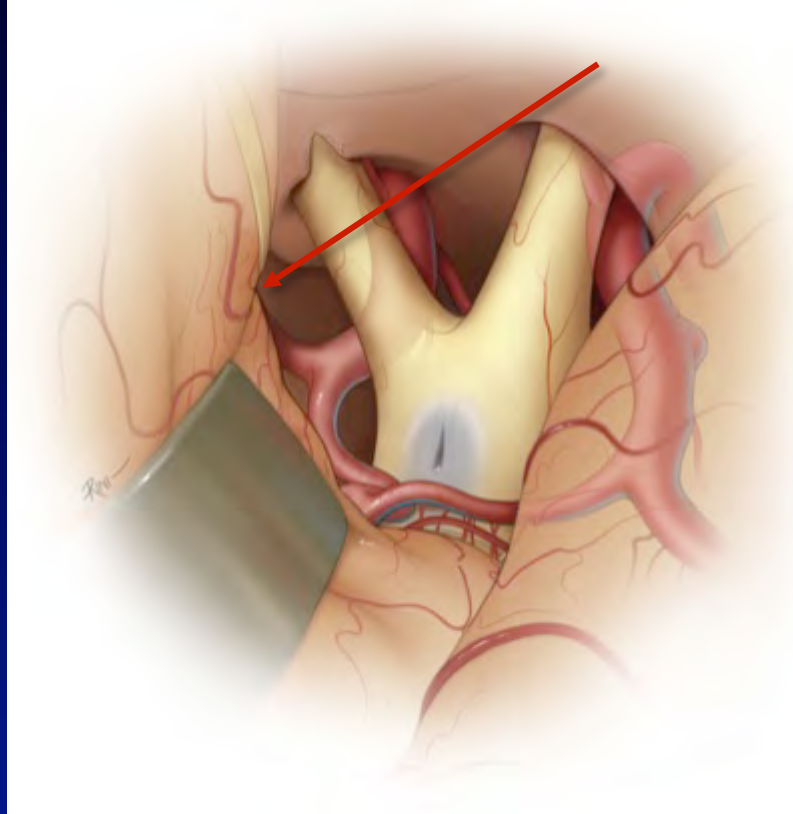


# Exposure of the Contralateral Internal Carotid Artery Bifurcation

- ICA bifurcation exposed in 100% of specimens
- Optimum corridor is supracarotid space



# Exposure of the Contralateral MCA Bifurcation



- M1 segment: range 7.0-26.0 mm, mean 13.5 mm
- Successful exposure if M1 segment  $\leq$  14 mm
- MCA bifurcation exposed in 62% of specimens

# Successful Contralateral Exposure by Artery Site

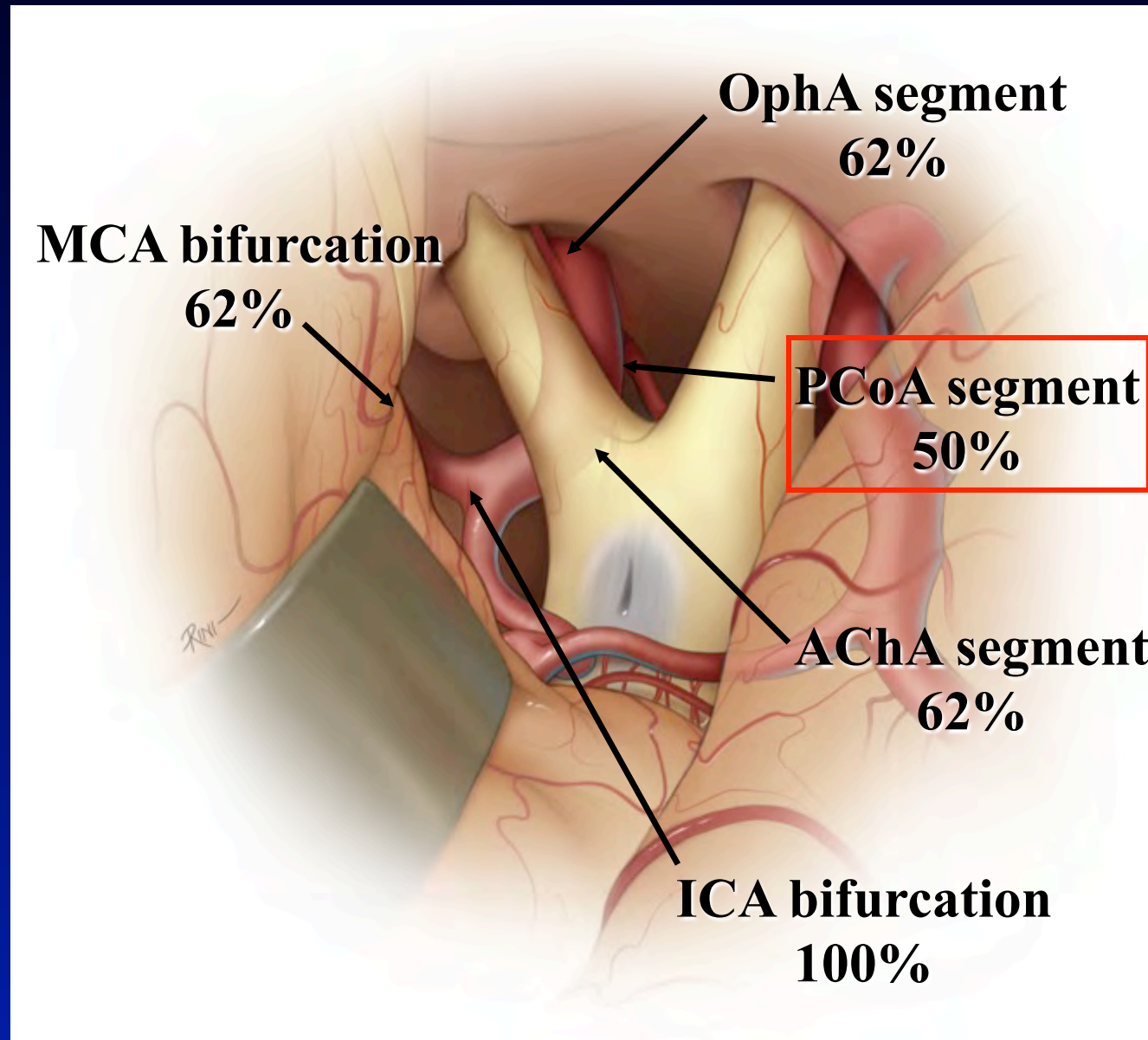


TABLE 2

Summary of clinical characteristics and treatment in 23 patients with bilateral supratentorial aneurysms\*

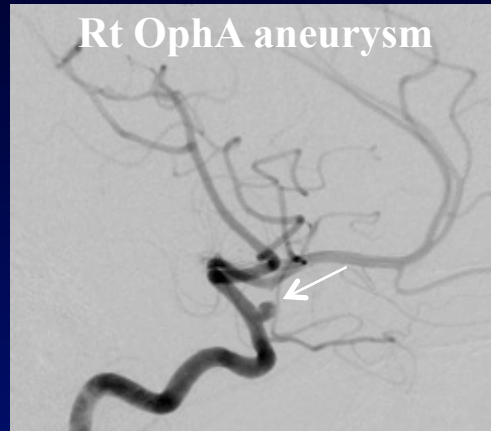
Case No.	Presentation	Hunt & Hess Grade	Aneurysm Site		Treatment	Comments
			Rt	Lt		
1	SAH	III	MCA, M <sub>1</sub>	PCoA	CAP, rt side	successful, all aneurysms clipped
2	unruptured	0	MCA	OA, ACoA	BiCr, 1 op	CAP not attempted, complex vascular anatomy
3	SAH	0	MCA (3)	MCA, PCoA	BiCr, 1 op	CAP not attempted, complex vascular anatomy
4	SAH	II	PCoA	OA	BiCr, 2 ops	CAP not attempted, complex vascular anatomy
5	SAH	I	MCA	MCA (2)	BiCr, 2 ops	CAP not attempted, complex vascular anatomy
6	SAH	III	PCoA	PCoA	CAP, rt side	negative exploration, lt PCoA infundibulum
7	SAH	I	PCoA	ICA term, sup hyp	CAP, lt side	successful, all aneurysms clipped
8	unruptured	0	MCA, ICA term, M <sub>1</sub>	MCA, ICA term	BiCr, 2 ops	CAP not attempted, complex vascular anatomy
9	SAH	II	PCoA	MCA	BiCr, 2 ops	CAP not attempted, complex vascular anatomy
10	SAH	I	PCoA, MCA	PCoA, MCA	BiCr, 2 ops	CAP not attempted, complex vascular anatomy
11	SAH, ICH	I	MCA, OA	OA	no surgery	suspected mycotic aneurysms
12	unruptured	0	PCoA	MCA, PCoA	Cr, rt side only	CAP not attempted, complex vascular anatomy
13	unruptured	0	MCA	MCA	Cr, rt side only	lt MCA aneurysm to be followed
14	SAH	I	PCoA	ICA term	BiCr, 1 op	CAP not attempted, brain swelling
15	SAH	III	PCoA	PCoA	CAP, lt side	CAP aborted, brain swelling
16	SAH	I	PCoA	PCoA	CAP, rt side	CAP aborted, brain swelling
17	SAH	II	PCoA, MCA	OA	CAP, rt side	successful, all aneurysms clipped
18	unruptured	0	MCA, ICA term	ICA term	CAP, rt side	successful, all aneurysms clipped
19	unruptured	0	PCoA	PCoA	CAP, rt side	successful, all aneurysms clipped
20	unruptured	0	OA	MCA	Cr, rt side only	small lt MCA aneurysm to be followed
21	SAH	III	PCoA, MCA	PCoA, M <sub>1</sub>	BiCr, 2 ops	CAP not attempted, complex vascular anatomy
22	SAH	I	PCoA	PCoA	CAP, rt side	successful, all aneurysms clipped
23	SAH	I	PCoA	MCA	Cr, rt side only	CAP not attempted, complex vascular anatomy

\* ACoA = anterior communicating artery; BiCr 1 op = bilateral craniotomy in one operating room session; BiCr 2 ops = bilateral craniotomy in two separate operating room sessions; CAP = contralateral approach; Cr = unilateral craniotomy; ICA term = ICA termination; ICH = intracerebral hemorrhage; sup hyp = superior hypophyseal artery.

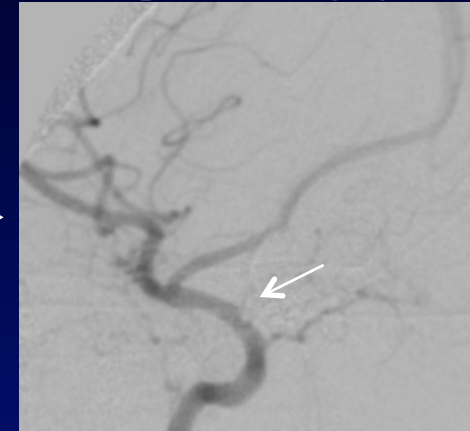


# 50 year-old female with incidental, unruptured right OphA and left ICA termination aneurysms approached from RIGHT craniotomy

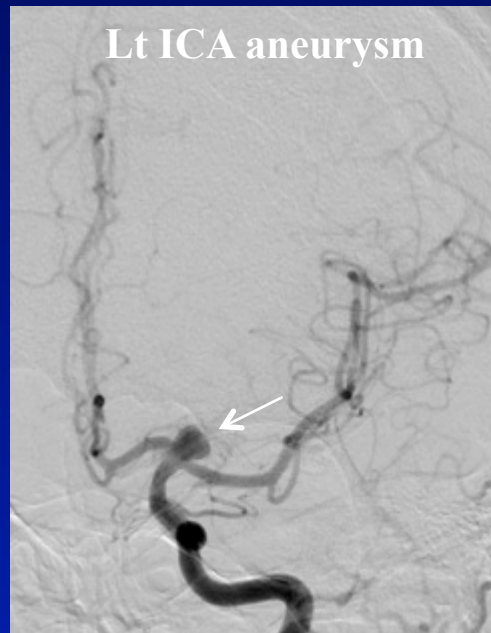
**Right  
Craniotomy**  
Right  
ophthalmic  
aneurysm



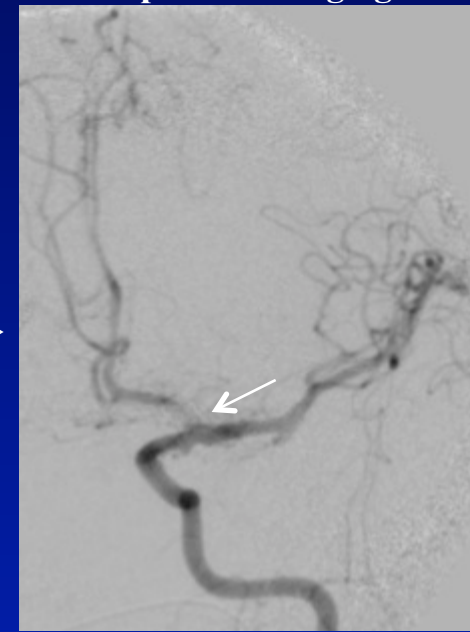
**Intraoperative Angiogram**



**Left  
ICA  
termination  
aneurysm**



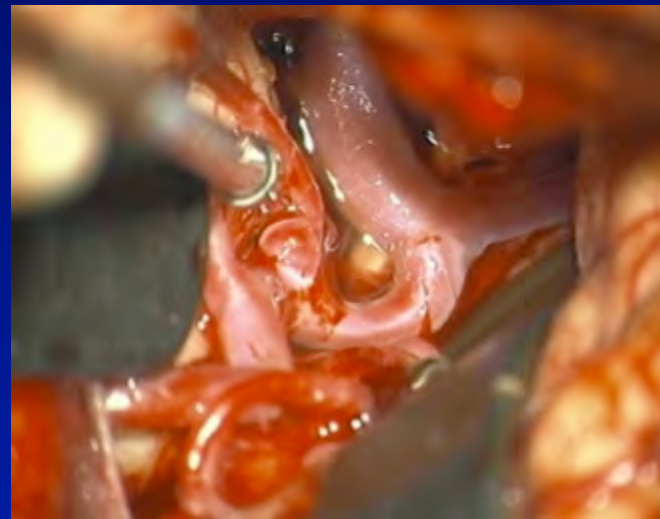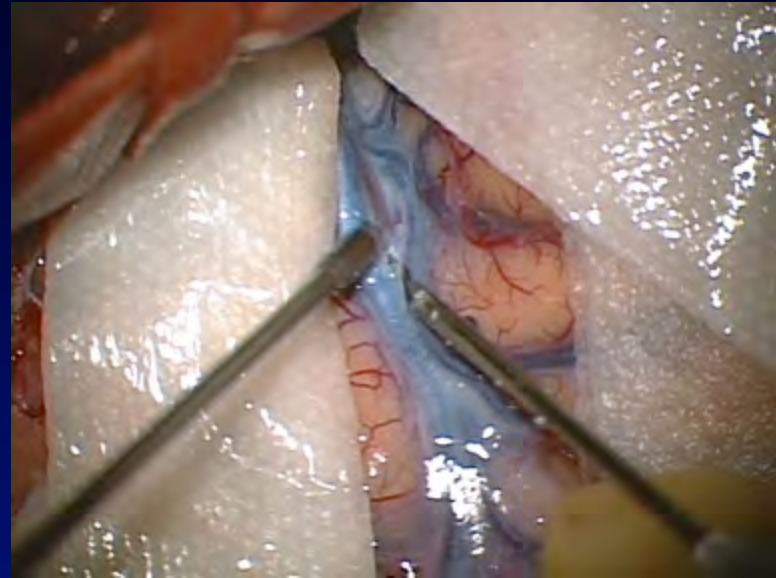
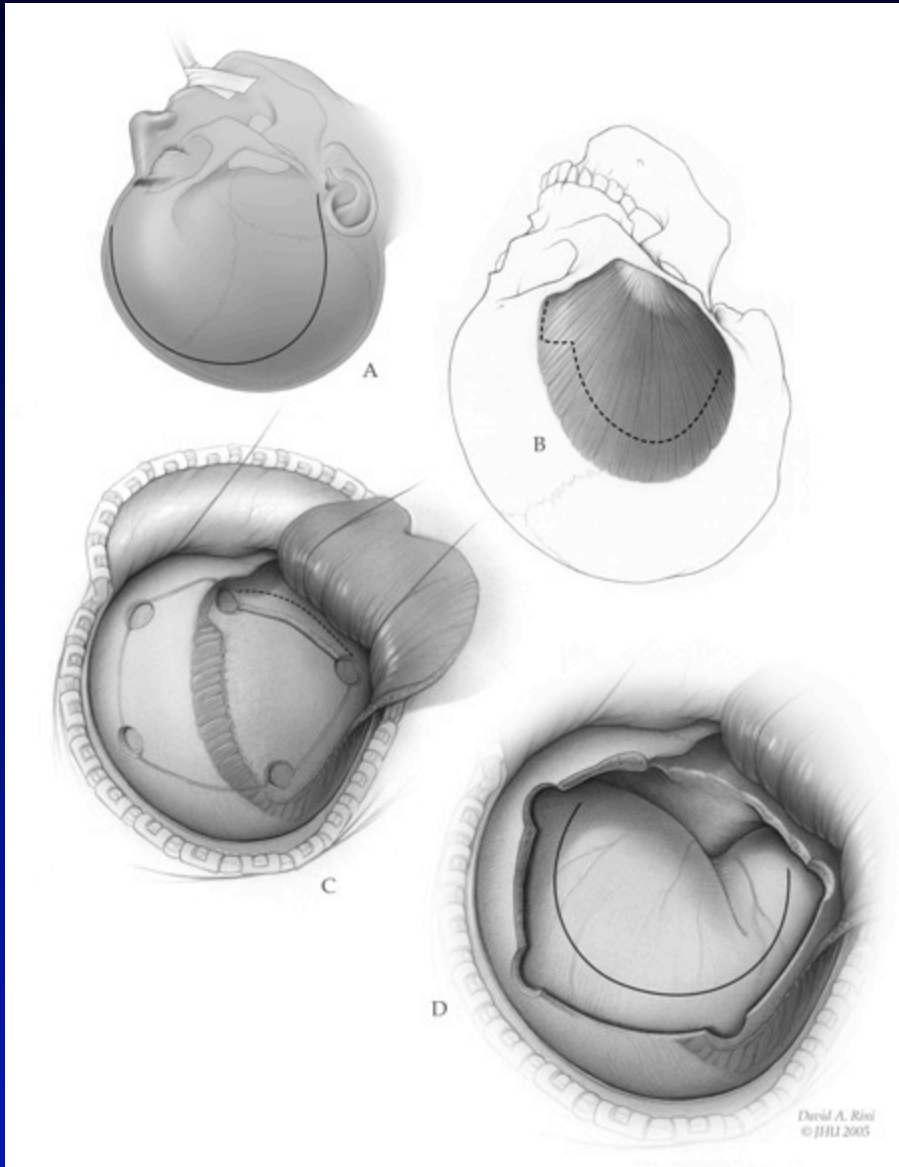
**Intraoperative Angiogram**



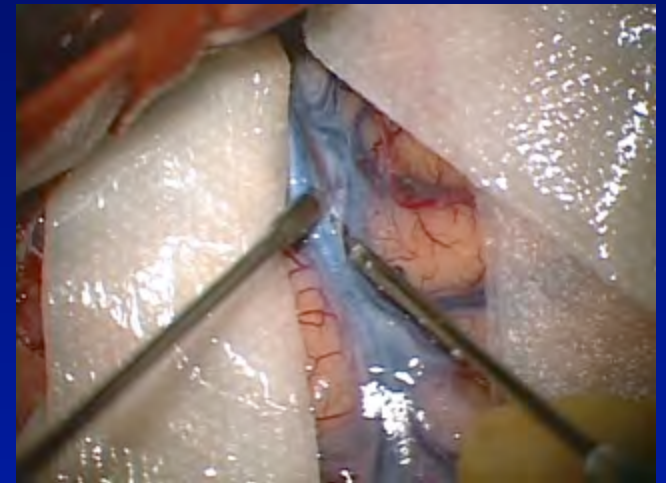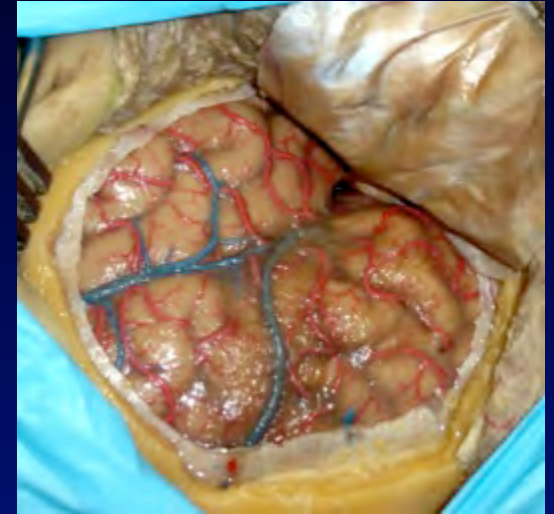
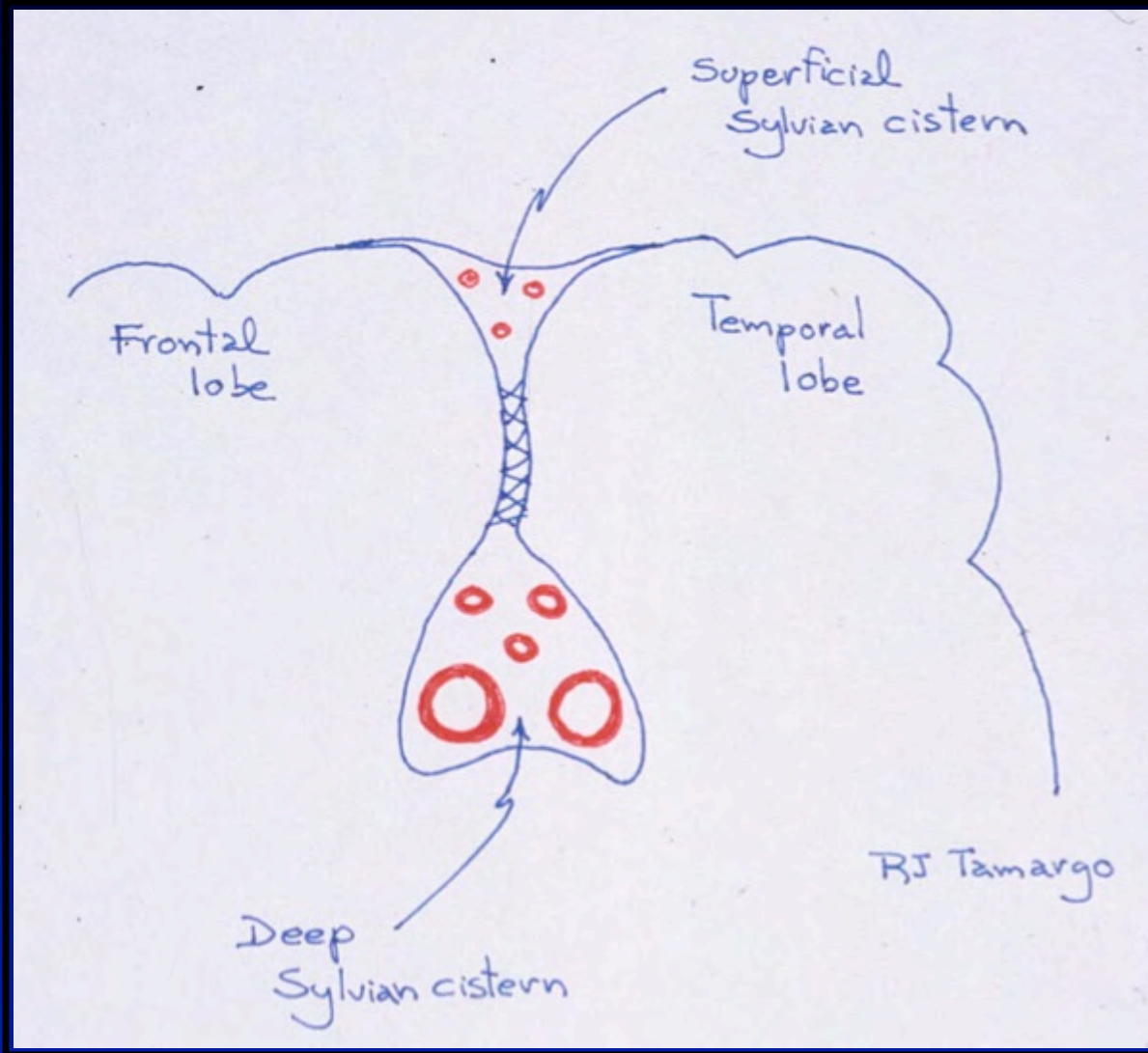
# Contralateral (CL) Approach: Ten Steps

1. Wide and low frontosphenotemporal craniotomy
2. Opening the ipsilateral Sylvian fissure
3. Dissection and clipping of ipsilateral aneurysm
4. Dissection of entire optic apparatus
5. Puncturing the lamina terminalis
6. Dissection of CL optic nerve
7. Division of CL falciform fold (Drilling of clinoid?)
8. Exploration of interoptic triangle (proximal control)
9. Exploration of opticocarotid triangle
10. Dissection and clipping of CL aneurysms

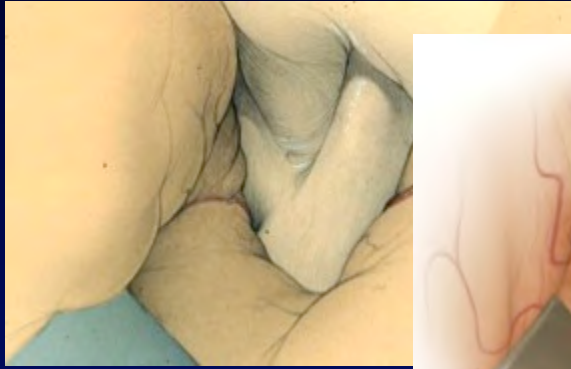
# Pterional Craniotomy for Contralateral Approach



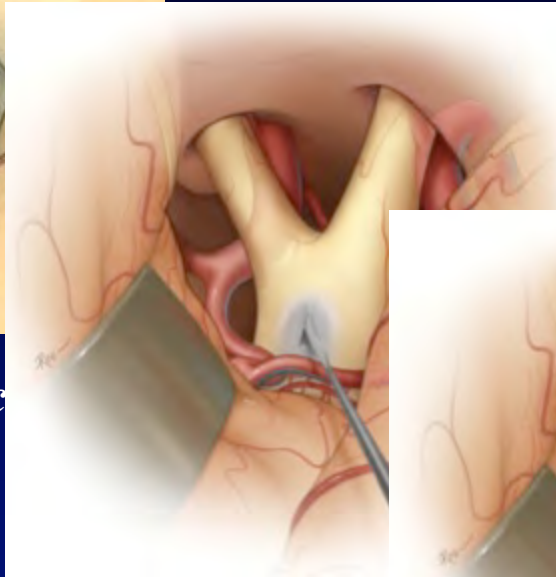
# The Superficial and Deep Compartments of the Sylvian Fissure



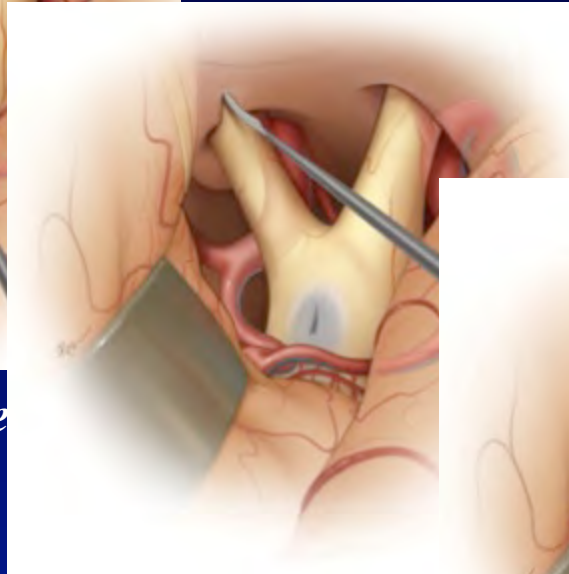
# Steps for Exposure of Contralateral Aneurysms



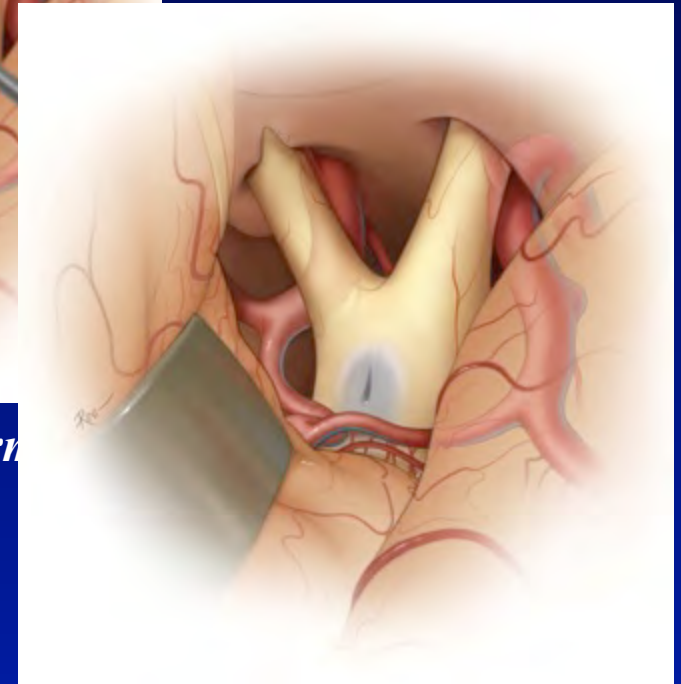
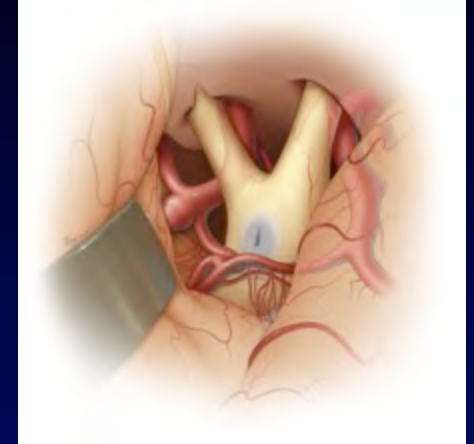
*Exposure of entire optic chiasm*



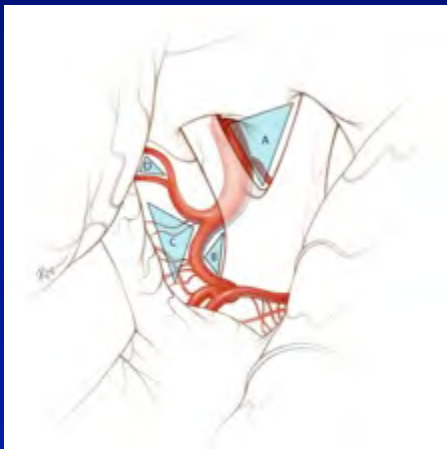
*Incision of lamina terebra*



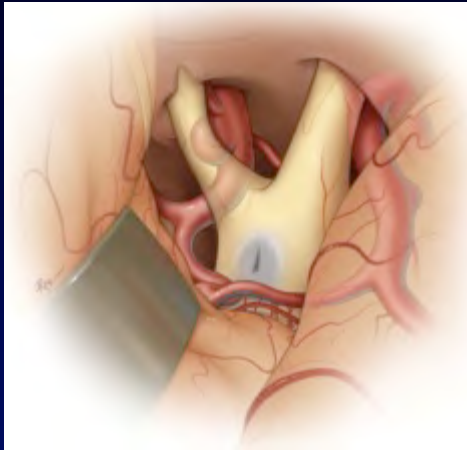*Division of falciform ligament*



*Full contralateral exposure*

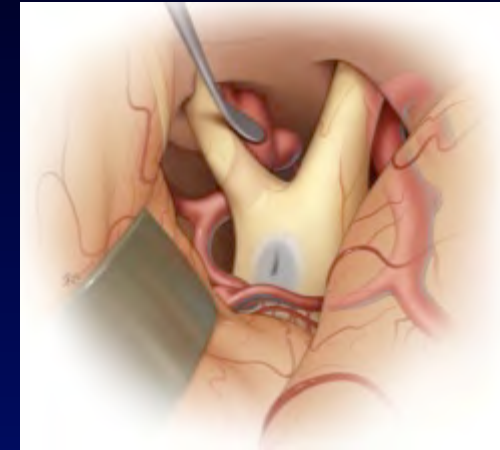
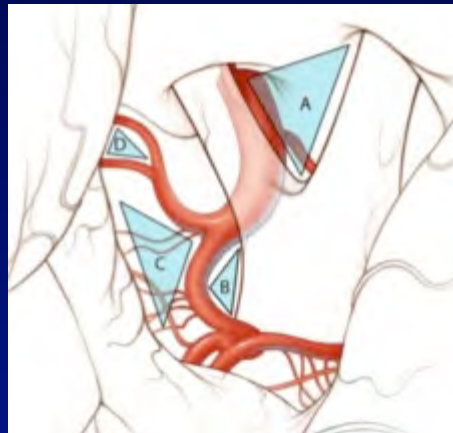
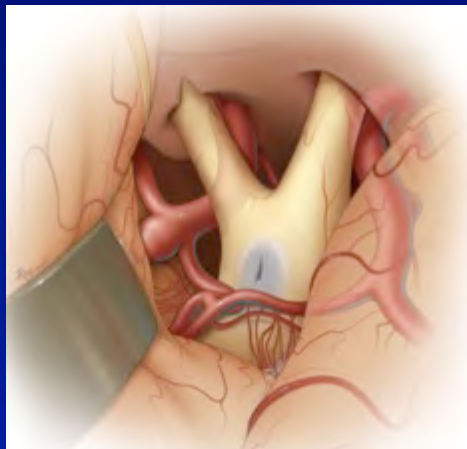


# Exposures of Contralateral Aneurysms



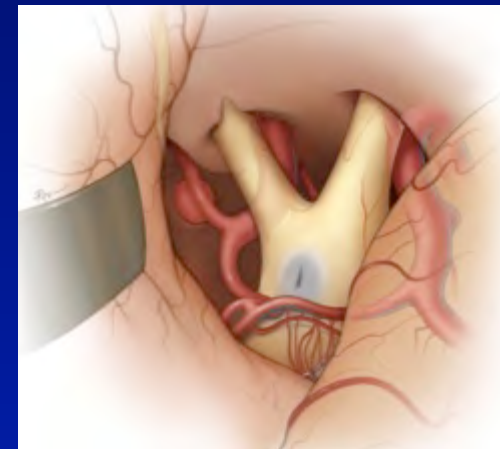
*Ophthalmic region aneurysm*

*Carotid termination aneurysm*



*Communicating region aneurysm*

*M1 segment aneurysm*



## OPERATIVE NUANCES

### CONTRALATERAL APPROACHES TO MULTIPLE CEREBRAL ANEURYSMS

Richard E. Clatterback, M.D., Ph.D.

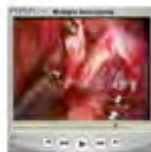Department of Neurological Surgery,  
The Johns Hopkins University School of Medicine,  
Baltimore, Maryland

Rafael J. Tamargo, M.D.

Department of Neurological Surgery,  
The Johns Hopkins University School of Medicine,  
Baltimore, Maryland

Reprint requests:  
Rafael J. Tamargo, M.D.,  
Meyer 8-181,  
600 North Wolfe Street,  
Baltimore, MD 21287.  
Email: rtamarg@jhmi.edu

Received, November 22, 2004.  
Accepted, January 20, 2005.



NOT INFREQUENTLY, PATIENTS with bilateral cerebral aneurysms are encountered. In such patients, the ability to treat bilateral aneurysms through a unilateral approach spares the patient the risk and inconvenience associated with a separate craniotomy. The contralateral approach for aneurysm repair is technically feasible and safe in appropriately selected patients. Herein, we review our technique for maximizing contralateral exposure and clipping contralateral aneurysms through the four anatomic triangles that serve as corridors in this approach.

**KEY WORDS:** Contralateral approach, Microsurgery, Multiple cerebral aneurysms

*Neurosurgery* 57(ONS Suppl 1):ONS-160-ONS-163, 2005

DOI: 10.1227/01.NEU.0000163661.37465.68

Multiple intracranial aneurysms are present in 14 to 34% of patients with intracranial aneurysms at presentation (6), and in 20 to 40% of these patients, the aneurysms are bilateral (1, 6). This means that roughly 3 to 13% of patients diagnosed with aneurysms have bilateral disease. The ability to treat these patients when feasible through a unilateral craniotomy offers the obvious advantage of avoiding a second craniotomy.

Several authors have reported clipping of contralateral aneurysms in case series and case reports (1-4, 7-9). We previously published a microsurgical anatomic study of the contralateral exposure for the most common sites of anterior circulation aneurysms (5) and completed detailed morphometry to establish a working set of guidelines for neurosurgeons to consult when considering contralateral approaches. We present here our thoughts on patient selection as well as the tenets for approaches to contralateral aneurysms. The basic tenets for all aneurysm surgery, including proximal vascular control, sharp microdissection, and meticulous preservation of perforators, also clearly apply to contralateral approaches.

#### PATIENT SELECTION

As we previously reported (5), not all anterior circulation aneurysms can be accessed readily via a contralateral approach. In patients with bilateral aneurysms, the selection of the contralateral approach takes into consideration both the patient's clinical condition and specific anat-

omy. Contralateral lesions that otherwise may be exposed easily also may be more difficult to expose in patients with subarachnoid hemorrhage. Brain swelling and hydrocephalus typically encountered in these patients may make excessive retraction force necessary for contralateral exposure. Dense, inflamed arachnoid adhesions in this setting also can make adequate, safe contralateral exposure difficult.

In patients with unruptured aneurysms, the patient's anatomy will dictate the ease of contralateral exposure of the common anterior circulation aneurysm sites (ophthalmic, posterior communicating, internal carotid artery [ICA] terminus, and middle cerebral artery bifurcation). For the ophthalmic and posterior communicating locations, aneurysms with necks that are located more medially on the ICA are more favorable for a contralateral approach. In our microsurgical study (5), exposure of the middle cerebral artery bifurcation was possible only if the M1 segment was 14 mm or less in length, while the ICA terminus was the most consistently exposed location.

#### CONTRALATERAL APPROACH

(see video at web site)

##### Low Fronto-orbital Extension of the Frontosphenotemporal Craniotomy and Ipsilateral Exposure

The ipsilateral exposure begins with a standard frontosphenotemporal (pterional) craniotomy. To obtain the additional working space

#### CONTRALATERAL APPROACH TO ANEURYSMS

preparation of the video and David Rini, M.F.A., for his medical illustrations. We received no financial support or have no financial interest in the material presented in this manuscript.

#### COMMENTS

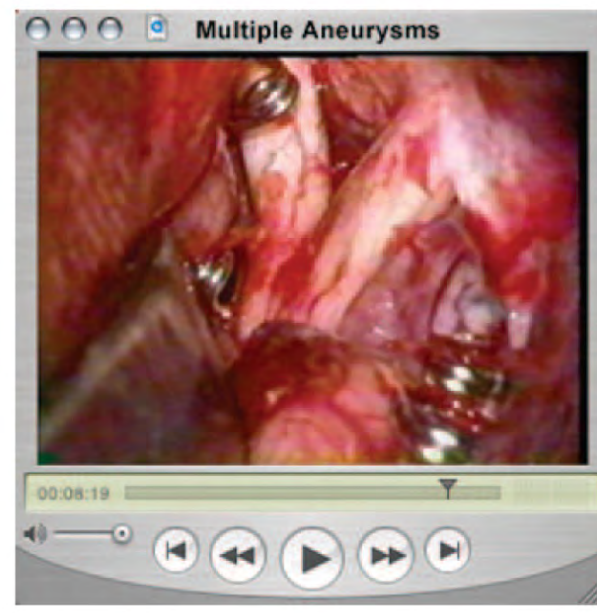This operative nuance article nicely illustrates techniques for the surgical exposure of contralateral aneurysms. Other adjunctive techniques that may be useful in such exposures include the use of lumbar subarachnoid drainage for additional cerebrospinal fluid withdrawal and brain relaxation, as well as the addition of a modified orbitozygomatic extension to the described craniotomy (1).

Seipideh Amin-Hanjani  
Robert F. Spetzler  
Phoenix, Arizona

1. Lemole GM, Herin JS, Zabramski JM, Spetzler RF: Modifications to the orbitozygomatic approach. *J Neurosurg* 99:924-930, 2003.

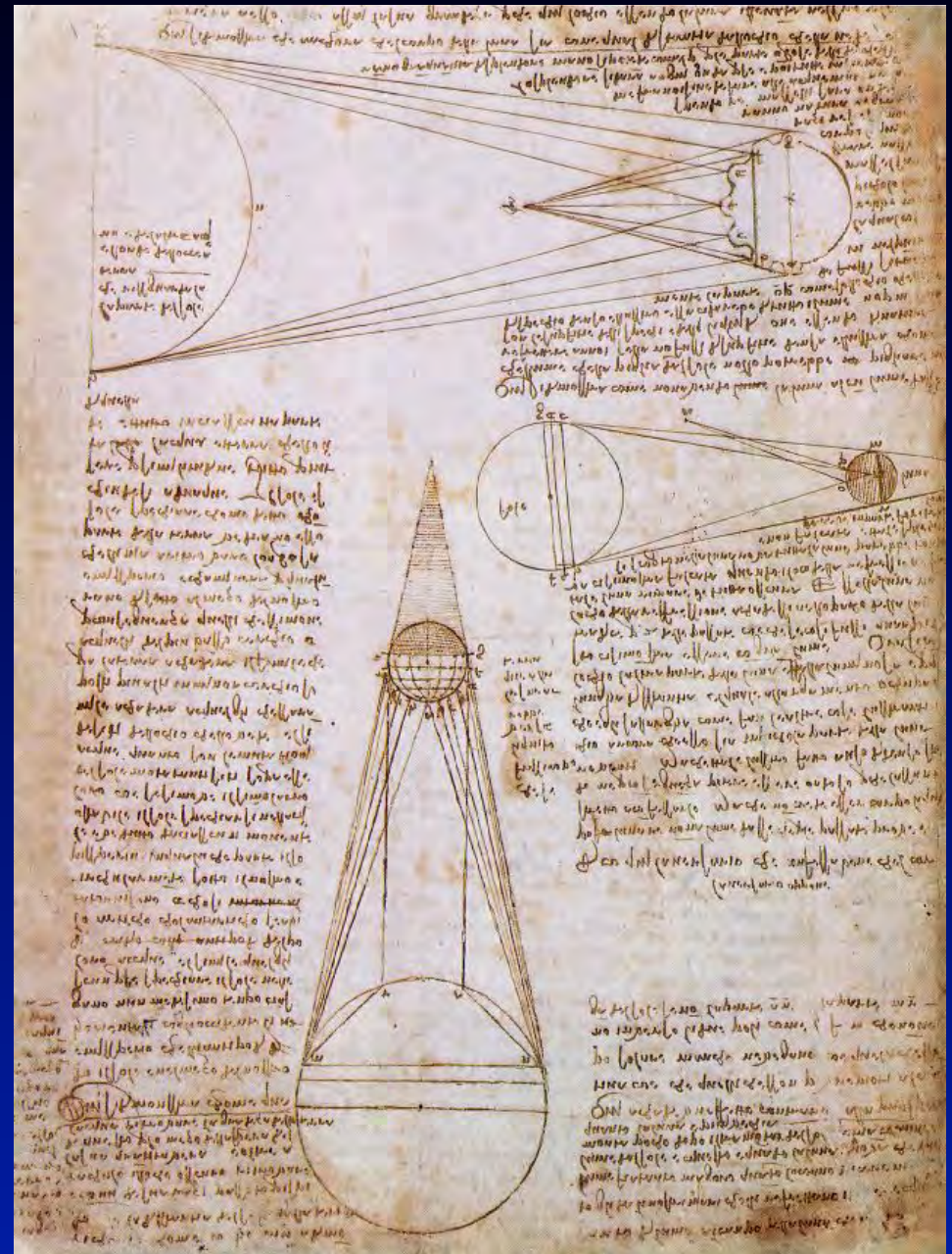
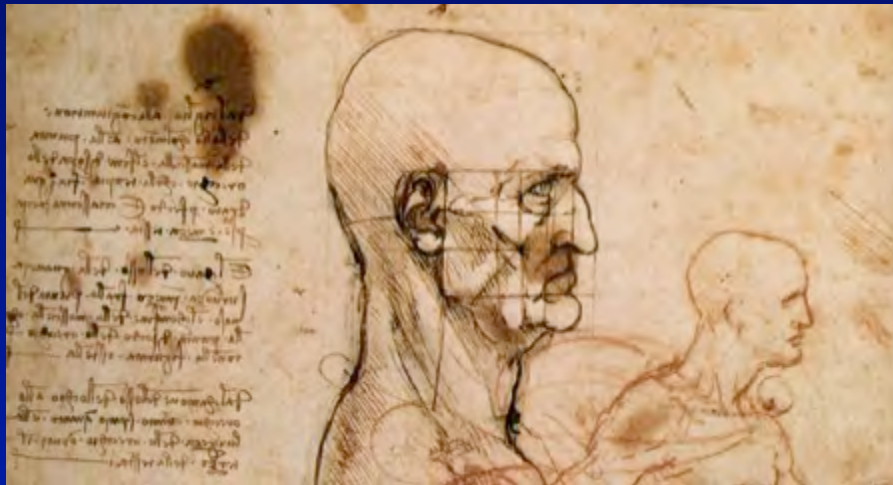This report reviews the concerns regarding the clipping of aneurysms from a contralateral approach. The various anatomical landmarks that demarcate corridors of dissection are nicely outlined. Clipping contralateral aneurysms during elective cases for unruptured aneurysms may have a benefit in saving the patient a future craniotomy. Whether or not the added time, dissection, and retraction is justified in a patient with a ruptured aneurysm and an incidental contralateral aneurysm, remains to be determined.

Robert A. Solomon  
New York, New York



# Contralateral Approaches to Bilateral Aneurysms: Questions

- 1) When should it be attempted?
- 2) How frequently is it successful?
- 3) What are the patient outcomes?



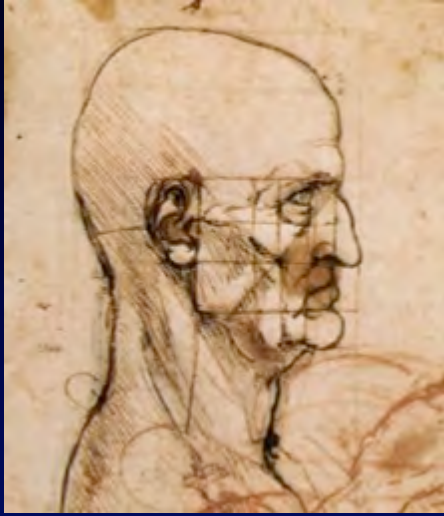

# Personal Prospective Series



1. May 1992 to April 2010 (18 years)
2. Out of 613 total cases, 72 (12%) had bilateral supratentorial aneurysms
3. Contralateral approach performed in 60 patients
3. Of the 60 cases:
  - 67% were unruptured and 33% had SAH
  - Average of 2.4 aneurysms per patient
  - Total of 144 aneurysms (69 contralateral)
  - All SAH patients were operated within 48 hours of presentation

## Surgical Selection Criteria



1. Only aneurysms less than 11 mm were considered for the contralateral approach
2. In SAH cases, the craniotomy was performed on the side of the ruptured aneurysm
3. In unruptured cases, the craniotomy was performed either:
  - on the side of the largest aneurysm
  - or
  - on the side of the PCoA/AChA aneurysm, which are most difficult contralaterally

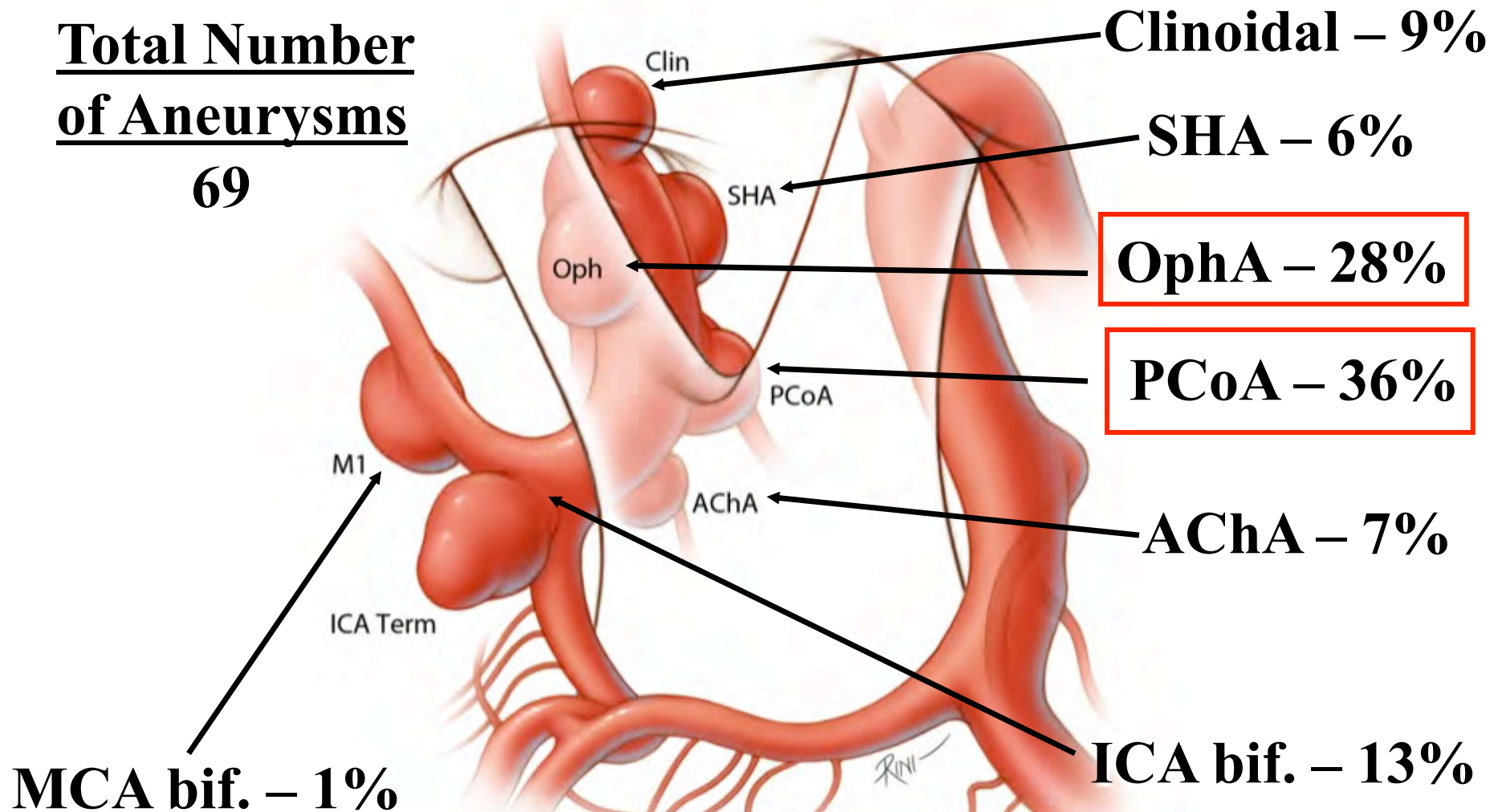


# Locations of 69 Contralateral Aneurysms

(From a total of 144 aneurysms in 60 patients)

Total Number  
of Aneurysms

69



# Why and how frequently was the contralateral approach NOT pursued?

Not pursued due to complexity of ipsilateral or contralateral aneurysm (e.g.,  $> 25$  mm) or site of contralateral aneurysm (e.g., distal MCA)

## 1. Unruptured aneurysms:

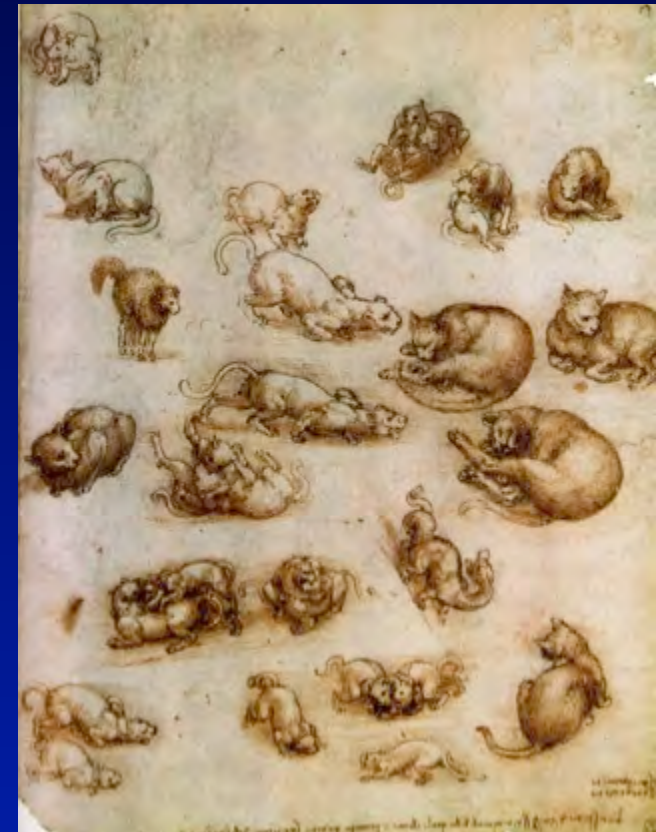- Not pursued in 13% of cases (6/46)

## 2. SAH:

- Not pursued in 23% of cases (6/26)

## 3. Total:

- Not pursued in 17% of cases (12/72)



# When planned and pursued (in 60 out of 72 cases), how frequently was the contralateral approach successful?

## 1. In unruptured cases:

- CL approach completed successfully in 85% (34/40)
- Aneurysm exposed but not repaired in 15% (6/40)

All 6 with PCoA aneurysms


## 2. In SAH cases:

- CL approach completed successfully in 45% (9/20)
- CL approach abandoned in 55% (11/20)

All 11 because of brain edema

## 3. In total:

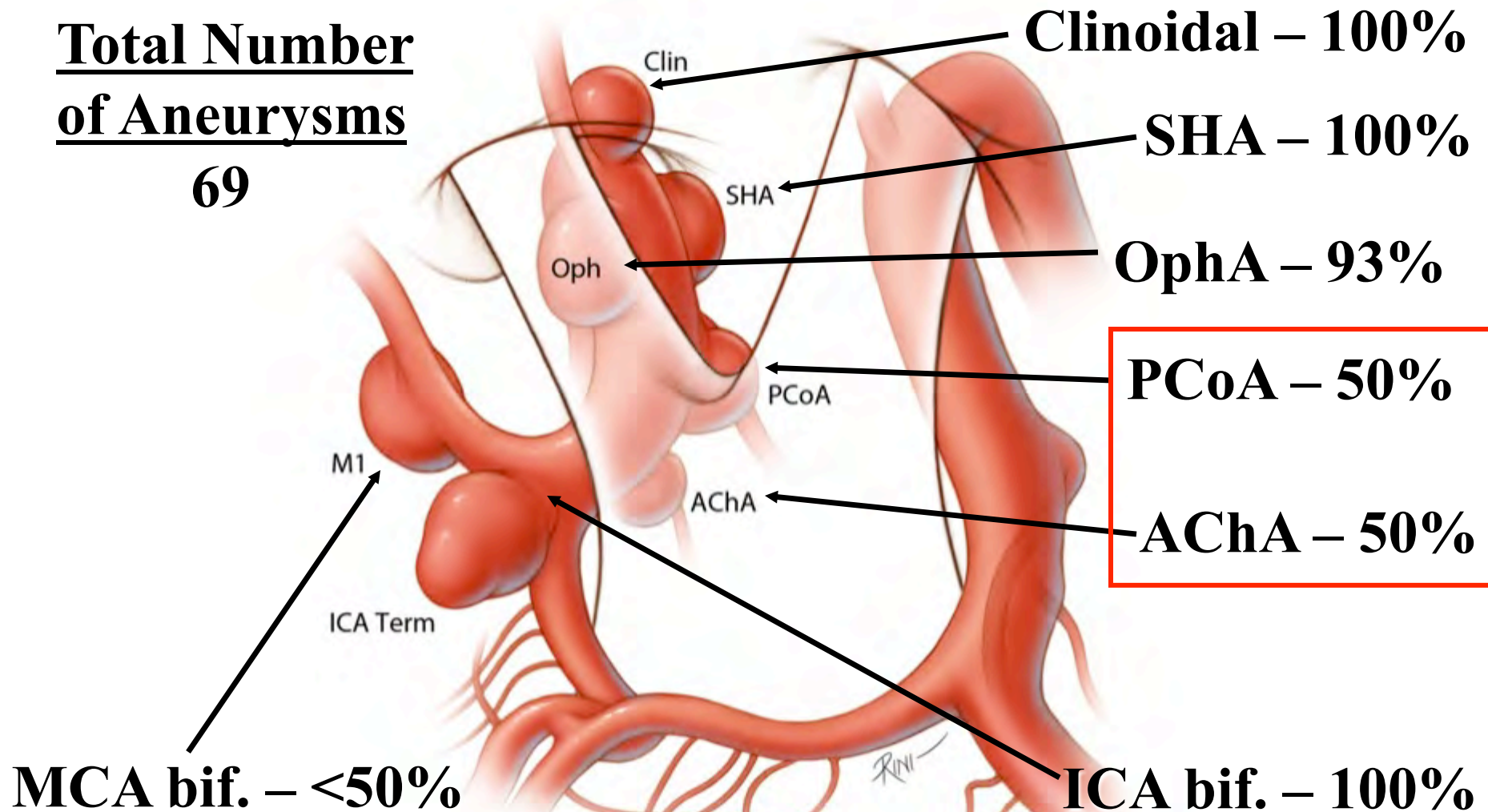
- CL approach completed successfully in 72% (43/60)
- Aneurysm exposed but not clipped in 10% (6/60)
- CL approach abandoned in 18% (11/60)

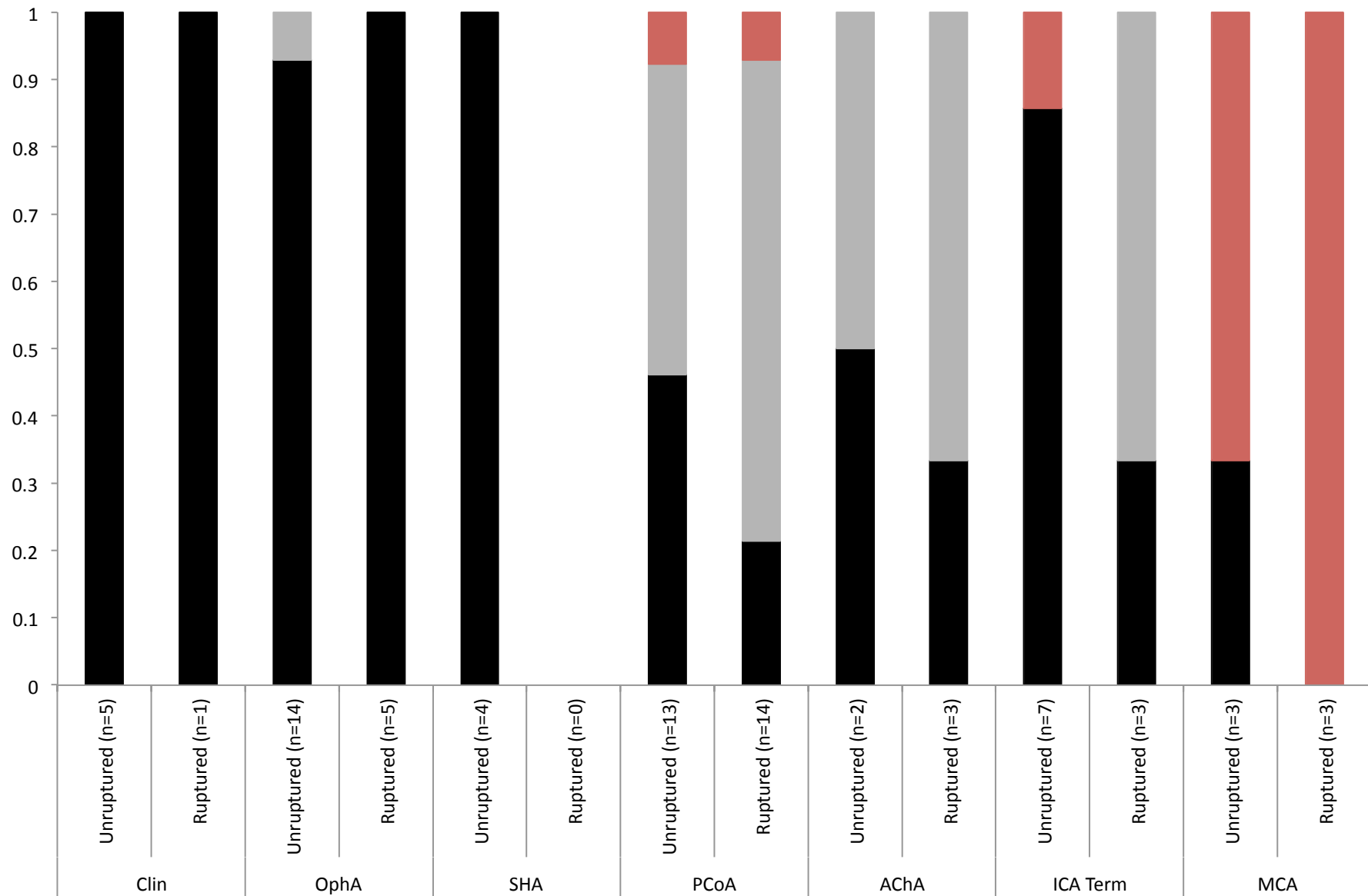


# Rate of Successful Repair of Unruptured Contralateral Aneurysms

Total Number  
of Aneurysms

69





- CL aneurysm successfully treated
- CL aneurysm clipping abandoned because of poor visualization or edema
- CL pterional approach not attempted due to complexity of the CL aneurysm

# DEMOGRAPHICS

## **2144 Standard Approach Patients compared to 60 Contralateral Approach Patients**

	<b>Standard Care</b>	<b>Contralateral Craniotomy</b>
Number of patients	N=2144	N=60
Age (Mean $\pm$ SD)	52.8 $\pm$ 13.4	51.0 $\pm$ 10.3
Gender	Female 74.9%	Female 81.7%
Race	Caucasian: 66.4% African-American: 29.4% Hispanic, Asian: 4.2%	Caucasian: 56.7% African-American: 36.7% Hispanic, Asian: 6.7%
Aneurysm Presentation	SAH 50.2%	SAH 33.3%
Form of Therapy	Craniotomy 70% Endovascular 30%	Craniotomy 100%



# Glasgow Outcome Score (GOS)

## GOS

## Description

- |   |  |
|---|--|
| 5 | Good recovery, resumption of normal life       |
| 4 | Independent lifestyle with moderate disability |
| 3 | Severe disability, dependent for daily support |
| 2 | Persistent vegetative state                    |
| 1 | Death  |

Jennett B, Bond M Lancet 1:480, 1975

# **OUTCOMES (GOS at Discharge)**

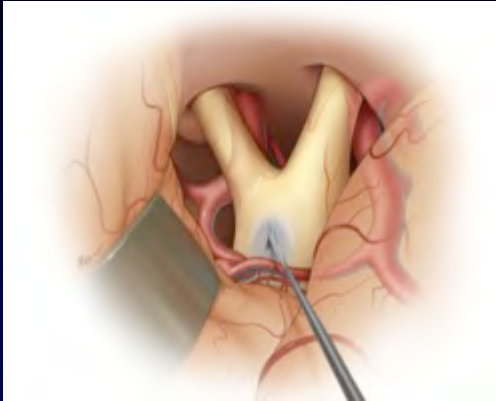
**2144 Standard Approach Patients**

**compared to**

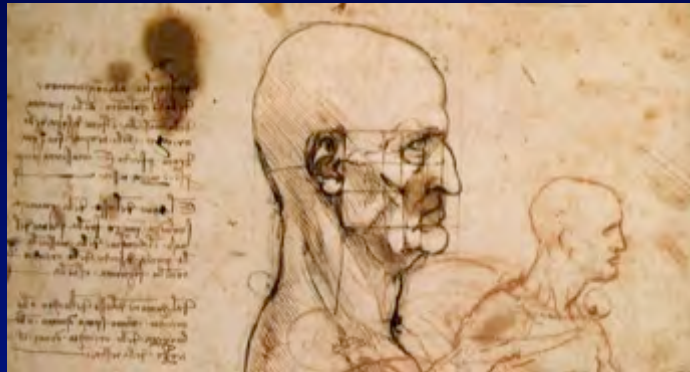**60 Contralateral Approach Patients**

	<b>Standard Care (Total n=2144)</b>	<b>Contralateral Craniotomy (Total n=60)</b>	<b>p-value</b>
Unruptured	4.6 ± 0.8 (n=1046)	4.5 ± 0.8 (n=40)	p = 0.64
SAH Grade 1	4.1 ± 1.1 (n=519)	4.0 ± 0.7 (n=13)	p = 0.77
SAH Grade 2	3.4 ± 1.2 (n=260)	4.5 ± 0.7 (n=2)	p = 0.35
SAH Grade 3	3.0 ± 1.0 (n=119)	1.0 (n=1)	p = 0.29
SAH Grade 4	2.4 ± 1.1 (n=126)	3.0 ± 0.0 (n=4)	p = 0.27
SAH Grade 5	1.9 ± 1.1 (n=74)	---	n/a

## Conclusions

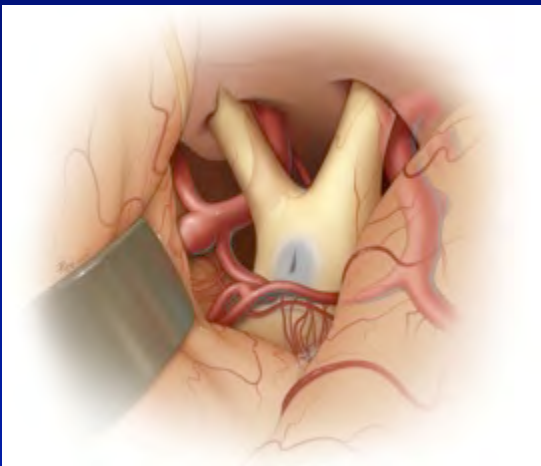


1. The contralateral (CL) approach is as safe as standard microsurgical or endovascular approaches in carefully selected patients




2. Clinoidal, OphA, SHA, and ICA termination aneurysms are most favorable for CL approach

3. PCoA, AChA, and MCA aneurysms are most difficult for CL approach



4. In the presence of SAH, the CL approach cannot be completed in 55% of cases

# The Johns Hopkins University School of Medicine Department of Neurosurgery



**Baltimore, Maryland**